



Experience of a single center in the treatment of rare malignant peripheral nerve sheath tumors during the years 1991–2021

Anna Ptchelintseva, Henrik Nuutinen, Juho Salo & Erkki Tukiainen

To cite this article: Anna Ptchelintseva, Henrik Nuutinen, Juho Salo & Erkki Tukiainen (2022): Experience of a single center in the treatment of rare malignant peripheral nerve sheath tumors during the years 1991–2021, Journal of Plastic Surgery and Hand Surgery, DOI: [10.1080/2000656X.2022.2131559](https://doi.org/10.1080/2000656X.2022.2131559)

To link to this article: <https://doi.org/10.1080/2000656X.2022.2131559>



Published online: 16 Oct 2022.



Submit your article to this journal [↗](#)



Article views: 26



View related articles [↗](#)



View Crossmark data [↗](#)

ARTICLE

Experience of a single center in the treatment of rare malignant peripheral nerve sheath tumors during the years 1991–2021

Anna Ptchelintseva^{a,b}, Henrik Nuutinen^{a,c}, Juho Salo^b and Erkki Tukiainen^b

^aFaculty of Medicine, University of Eastern Finland, Kuopio, Finland; ^bDepartment of Plastic Surgery, Helsinki University Hospital, Helsinki, Finland; ^cDepartment of Plastic Surgery, Kuopio University Hospital, Kuopio, Finland

ABSTRACT

Malignant peripheral nerve sheath tumor (MPNST) is a rare sarcoma with a poor prognosis, as the aggressive types of this cancer tend to grow rapidly and metastasize frequently. MPNST is associated with neurofibromatosis type 1 gene mutation. The minority of cases arise secondary to radiation therapy or sporadically. The primary treatment for MPNST is early surgical resection of the tumor. The aim of this study was to retrospectively evaluate the outcome of the treatment of MPNST in Helsinki University Hospital from the years 1991 to 2021. Fourteen MPNST cases were evaluated in this study retrospectively. Descriptive statistical analysis was performed on the collected patient data. Marginal resection was completed in nine cases, wide margins were achieved in three cases, and in two cases the final histological examination of the specimen revealed intralesional removal. During the follow-up time of 36.7 ± 12.1 months, all patients who underwent wide margin resection were alive. One patient died 22 months after intralesional resection and six within 38.3 ± 30.9 months of marginal resection. Seventy-one percent of tumor surgeries resulted in Clavien-Dindo class 3b complications, reflecting the complexity of the surgeries. The aggressive nature of MPNST and the large size of these tumors requires extensive surgery, which can lead to complications. The prognosis of MPNST needs improvement.

ARTICLE HISTORY

Received 21 April 2022
Revised 30 August 2022
Accepted 28 September 2022

KEYWORDS

Resection margin; adjuvant treatment; reconstructive surgery; NF1

Introduction

Malignant peripheral nerve sheath tumor (MPNST) is a rare tumor, which accounts for 5–10% of all soft tissue sarcomas [1]. Cancer develops in perineural cells, most commonly in Schwann cells but also in fibroblasts. Tumors commonly occur in the confluence of large nerves, such as the sciatic nerve or its branches, sacral or brachial plexus [2]. Most commonly, primary tumors are situated in the lower extremities but rarely they may appear in the brain or internal organs [1].

The main clinical symptoms of MPNST are a mass or swelling in the soft tissue which gradually increases in size and may cause local or radicular pain, paresthesia, or paraparesis [3]. The diagnostics usually begins with a confirmation of a possible tumor using ultrasound imaging. To establish precise location, anatomy, and specific tumor characteristics, a contrast-enhanced MRI is the primary choice of imaging. The histopathology of the tumor is always confirmed by examining fine or core needle biopsy guided by ultrasound and previous MRI. The sample site is aimed to be taken from the most active vital area of the tumor.

Patients with small tumors located in the extremities have a better prognosis than those with large tumors especially if they are located along the trunk or head and neck area, as they are physically more noticeable [4]. The five-year survival rate varies between 16 and 52% depending on the size and location of the tumor, surgical resection margins, timing of diagnosis and intervention, predisposition to tumor growth, and stage [5,6].

Genetic background plays a significant role in the development of MPNST. Neurofibromatosis type 1 (NF1) patients have an

increased risk of developing MPNST, and every tenth individual with NF1 has a lifetime risk of developing MPNST. According to statistics, 25–50% of cancer cases develop in patients with a mutation of the NF1 gene [7]. NF1 gene mutation is a familial disorder, which causes the growth of benign tumors called neurofibromas along the nerves. Neurofibromas can turn malignant, and a study by Ducatman et al., along with several other studies, showed that 81% of MPNST cases developed from a pre-existing neurofibroma.

MPNST is usually diagnosed in patients aged 20–50 years, but 10–20% of cases are present in patients younger than 20 years. A minority of cases arise either sporadically or secondary to radiation therapy. Secondary cases are most prevalent in patients who have undergone radiotherapy for breast cancer or lymphoma [2]. In general, sarcomas induced by radiation therapy are known for their potential to have a worse outcome than primary MPNSTs. In addition, previous high-dose radiation usually prevents further radiotherapy [6,8].

The prognosis of MPNST is poor, as it is aggressive cancer that grows rapidly and metastasizes in 39% of patients, typically into the lungs [9]. Additionally, cancer has a local and metastatic recurrence rate between 40 and 68% depending on the original tumor size and location [10]. MPNST is considered to have one of the highest recurrence rates among soft tissue sarcomas [11].

Treatment of sarcomas requires multidisciplinary work involving specialists, such as pathologists, radiologists, surgeons, and oncologists, and hence sarcoma cases are primarily handled by sarcoma teams in university hospitals. The median overall survival of patients with metastatic disease as well as overall patient

quality of life increases when the patient undergoes modern treatment including various modalities and follow-up designed and implemented by these sarcoma teams [12].

Primary and the most effective treatment for MPNST is early surgical resection of the tumor. There is no single universal consensus regarding sufficient margin width, but wide margin excision (>10mm) is commonly the accepted margin for tumor resection. However, in some cases, smaller margins are accepted if there is a need to preserve unaffected major structures [13]. In certain cases, major surgical resection involving extremity amputation is performed, especially if the extremity is painful, paralytic, or infected.

Indications for the administration of adjuvant radiation therapy and chemotherapy are evaluated for each patient case individually based on the benefits and risks of each modality [10]. The treatment protocols for radiotherapy chosen for the patients in this study are based on recommendations presented by the Scandinavian Sarcoma Group [14]. There is no consensus on the role of chemotherapy in the treatment of advanced MPNST, but it is widely used as an adjunct in marginal and intralesional resections and in the treatment of metastasized MPNST [15]. In comparison with chemotherapy, radiation therapy has been shown to have a stronger impact on overall patient survival, especially in the treatment of high-grade tumors [16].

The aim of this study was to retrospectively study 14 case reports presented to Helsinki University Hospital with MPNST diagnosis. There are no previous studies published describing the treatment path and the success and complications of treatment for MPNST in Finland. The largest studies of MPNST were conducted by Watson et al. in 2017, which included 289 patients in the USA, and by Anghileri et al., with 205 patient cases in Italy.

Methods

Patients and statistical analysis

This investigation includes 14 tumor cases with a histologically confirmed diagnosis of MPNST during the years 1991–2021 presented to Helsinki University Hospital. Patient information was collected from the hospital's patient database. Clinicopathologic information was charted for every patient using IBM SPSS Statistics (version 27), including standard patient information, such as age, sex, and previous medical history (previous NF1 diagnosis). Additionally, tumor-specific information, such as number, grade, size, location, resection margins, performed reconstruction and possible amputation, time between diagnosis and operation, recurrence, treatment path, and metastases was also gathered.

Histopathologic classification of tumors was based on the Scandinavian Sarcoma Group's four-tier grading system, which was widely used during those years in the Scandinavian countries. Globally World Health Organization recommends the use of either the National Cancer Institute grading system or the French Federation of Cancer Centers Sarcoma Group system [17]. Recently also Helsinki University Hospital has changed to the use of three-grade systems. Possible side effects and complications arising from the operation or post-operatively were also collected.

All 14 tumors underwent the operation. Pre-surgical biopsy was always performed guided with preoperative MRI and ultrasound. Fine needle biopsies were aimed to be taken from the most active vital area in the tumor. In most cases, the core biopsy was not taken from the nerve, as it is extremely painful.

As this investigation focuses on tumor treatment, each tumor is discussed as its own individual case. The surgical plan was made according to the histology, grade, anatomical location of

the tumor, as well as the patient's general condition and preoperative treatment. Preoperative images were discussed thoroughly with musculoskeletal radiologists to establish appropriate margins both longitudinally within the nervous structures and circumferentially facing surrounding tissues.

The final resection margins for each tumor were determined by the pathologist's report presented to the tumor board. Where possible, margin width was quantified for statistical analysis; qualitative Enneking's classification of surgical margins was not used in this study [18]. We used the classification described in our department which is a modification of the TNM residual tumor (R) classification [19]. Resection was described as marginal (R1) if the tumor was removed as a whole but without the sufficient healthy tissue margin required to be classified as radical. Intralesional resection (R2) is a term used to describe incomplete resection of the tumor with macroscopically or microscopically visible malignant tissue left in the resection zone. The ideal radical resection (R0) refers to the complete removal of the tumor with 2–3 cm of healthy tissue margin or with an impermeable membrane, such as the periosteum or fascia [20].

Each patient's need for adjuvant therapy was individually assessed and designed by a multidisciplinary team (radiation therapy/chemotherapy or both) depending on tumor properties. The main form of chemotherapy was combined ifosfamide-doxorubicin (Adriamycin) treatment.

Results

The retrospective analysis included 13 patients: six males, and seven females, with the mean age at diagnosis 43.6 ± 20.9 years. One patient had two primary tumors, which are discussed and analyzed in this study as two separate tumor cases. Thus, the data presented in Table 1 varyingly depict results calculated by analyzing patient data ($n=13$) and tumor data ($n=14$). Eight (61.5%) patients had a pre-existing diagnosis of NF1, two patients (15.4%) had MPNST in a previously radiated field, and three patients (23.1%) were determined to have tumors of sporadic origin.

All 14 tumors qualified for surgical removal. Eleven tumors (78.6%) were histologically classified as high-grade sarcoma and three tumors (21.4%) as low-grade sarcoma. The mean tumor size of 7.9 ± 2.6 cm was calculated by averaging the length of the tumor stated in the pathologist's analysis of the operative specimen. Most of the primary tumors were located either in the lower extremities ($n=6$, 42.9%) or in the trunk ($n=6$, 42.9%). The remaining tumors were located on the head ($n=2$, 14.3%). The tumor location is shown in Figure 1.

The mean follow-up time for the tumors was 36.8 ± 23.6 months. Seven patients were reported to be alive at the time of the last follow-up (May 2021). Fifty percent of the studied subjects died on average 36.0 ± 28.8 months after the primary operation. Eleven patients (78.6%) experienced a recurrence of the disease: local recurrence was found in 4 patients, and metastatic disease in 7 patients. The primary location for metastasis was the lungs, and one patient additionally presented with nodal and liver metastasis.

Adjuvant treatment

The need for adjuvant treatment was evaluated for every tumor case individually in the multidisciplinary sarcoma group. Two tumors did not receive any adjuvant treatment pre- or post-operatively: one tumor was a low-grade tumor situated in the left

Table 1. Summary of data collected from analyzing 14 malignant peripheral nerve sheath tumor cases presented to Helsinki University Hospital during the years 1991–2021.

Number of operated tumors	14
Number of patients	13
Mean age at diagnosis, years \pm SD	43.6 \pm 20.9
Number of patients with neurofibromatosis type 1 (% of all patients)	8 (61.5)
Mean tumor size cm \pm SD	7.9 \pm 2.6
High grade (% of all tumors)	11 (78.6)
Recurrence of the disease, local or metastatic, number of tumors (%)	11 (78.6)
Lung metastasis as the first manifestation of recurrence (%)	7 (63.6) 7/11
Local recurrence (% of all patients with recurrence or metastasis)	4 (36.4) 4/11
Recurrence time after operation, months \pm SD	22.1 \pm 24.1
Follow-up time, months \pm SD	36.8 \pm 23.6
Alive (% of all tumors)	7 (50.0)
Survival, months after the first operation \pm SD	36.0 \pm 28.8
Oncological treatments: preoperative radiation therapy, number of tumors (%)	8 (57.1)

SD: standard deviation.

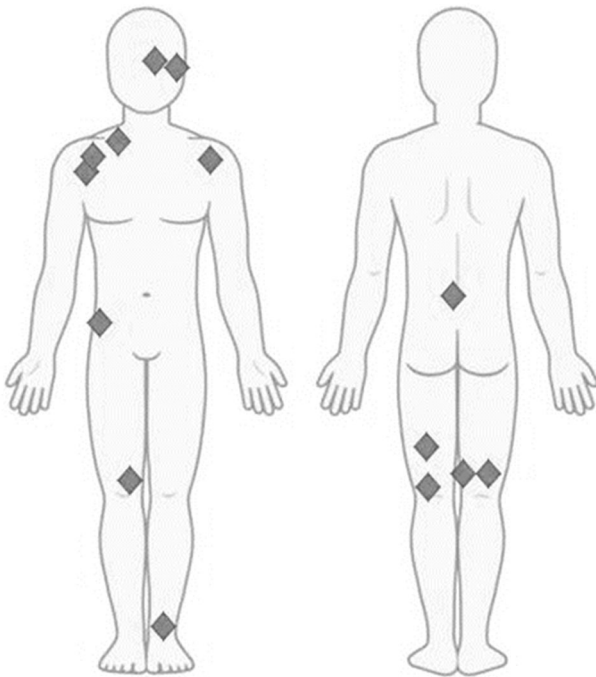


Figure 1. Location of the primary malignant peripheral nerve sheath tumors detected in 13 patient cases presented to Helsinki University Hospital during the years 1991–2021.

acromioclavicular AC joint and deltoid region and the other was a high-grade tumor situated in the right sciatic trunk above the popliteal fossa. Eight tumor cases (57.1%) received preoperative radiation therapy (60/2 Gy). One patient received additional preoperative chemotherapy. Three tumors received radiation therapy post-operatively; one received chemotherapy in addition. One patient received post-operative chemotherapy solely.

Surgical treatment and recurrence

The aim of the surgical resection was to remove malignant tissue with an appropriately wide margin if possible. Due to the demanding location of the tumors resulting from cancer's nature of afflicting deep and proximal nerve structures, only three tumors were resected with a wide margin. Nine tumors underwent marginal resection, and two tumors were resected intralesionally. Marginal resection resulted in recurrence (25.9 \pm 26.9 months) in eight out of nine tumor cases after primary surgery. Tumors that underwent wide resection developed recurrence 18.0 \pm 8.5 months

after primary operation in two out of three tumor cases. On the other hand, patients with tumors resected with wide margins were all alive during follow-up, which lasted 36.7 \pm 12.1 months. Only three tumors resected marginally were alive during a follow-up period of 41.2 \pm 27.3 months. Two tumors were resected with intralesional margin, and one remained alive during an average 17.0 \pm 7.1 month follow-up. The outcome of the surgical resections is summarized in Table 2.

Complications

All experienced complications were conventional post-operative complications associated with major surgery. Most of the surgeries carried out in tumor resection were complex and rare procedures. Individual data depicting every tumor's anatomical position, resection margin, type of surgery, metastatic recurrence, and Clavien-Dindo class are summarized in Table 3. Twenty-eight percent of the tumor resections experienced complications categorized as Clavien-Dindo class 1. Complications classified as Clavien-Dindo class 3b were associated with hematoma, poor blood circulation of the microvascular flap, post-surgical infection, and poor wound healing. There were no cases of perioperative death registered in this study, and the 30- and 90-day mortality rates were zero.

Reconstruction

Most patients underwent complex surgical procedures. Major resection surgeries included two rotationplasties, two forequarter amputations, and one Tikhoff-Linberg procedure [21]. Performance of both rotationplasties led to wide margin excision, while the forequarter amputations resulted in intralesional resection and served as life-sustaining surgeries.

Eleven flap reconstructions were performed. Pedicled flaps were used in four surgeries, in which a latissimus dorsi flap was used in three cases and a trapezius flap in one case. Free flap reconstruction was performed in seven cases: two anterolateral thigh flaps, two latissimus dorsi flaps, and single forehead, mucosal, and arm fillet flaps.

The indication for flap reconstructions was tissue loss, large post-operative cavity, and coverage of amputation stump to achieve functional stump and/or wound closure. Flaps were used wherever possible to prevent complications arising from post-operative radiation.

Nerve reconstruction was performed in two tumor surgeries. The sciatic nerve resections were located in the distal half of the thigh. The tibial portion of the sciatic nerve was reconstructed

Table 2. Summary of surgical resection outcomes for 14 malignant nerve sheath tumor cases treated in Helsinki University Hospital during the years 1991–2021.

Resection	Number of tumors	Recurrence of the disease, number of tumors (% of all)	If recurrence, months after the first operation \pm SD	Follow-up time (months)	Alive, number of tumors (% of all)	If death, months after the first operation months \pm SD
Intralesional	2	1 (50.0)	0.0 \pm 0.0	17.0 \pm 7.1	1 (50.0)	22.0 \pm (0.0)
Marginal	9	8 (88.9)	25.9 \pm 26.9	41.2 \pm 27.3	3 (33.3)	38.3 \pm 30.9
Radical	3	2 (66.6)	18.0 \pm 8.5	36.7 \pm 12.1	3 (100.0)	None

SD: standard deviation.

Table 3. Detailed description of the 14 malignant peripheral nerve sheath tumor cases treated in Helsinki University Hospital during the years 1991–2021: location, resection margin, surgery type, possible metastatic reoccurrence, and Clavien-Dindo class.

Tumor location and patient number	Resection	Reconstruction	Recurrence, local or metastatic (first manifestation)	Clavien-Dindo classification
1. Small nerve in left ankle	Marginal	ALT microvascular flap, LD microvascular flap after first flap loss	Lungs	3b
2a. Right sciatic trunk above popliteal fossa	Marginal	Reconstruction of tibial nerve with peroneus nerve graft	Lungs	1
2b. Left sciatic trunk hamstring region	Marginal	Reconstruction of tibial nerve with peroneus nerve graft	Lungs	1
3. Right hip crista iliaca region	Radical	LD microvascular flap, immediate evacuation of hematoma and pedicle thrombosis	Local	3b
4. Left popliteal fossa	Radical	Rotationplasty	Lungs	3b
5. Right brachial plexus	Intralesional	Forequarter amputation, reconstruction with arm fillet flap	Local	3b
6. Neck region of brachial plexus	Intralesional	Forequarter amputation, reconstruction using trapezius and LD flap	None	3b
7. Left post-auricular region	Marginal	ALT microvascular flap	Lungs	1
8. Left lower eyelid	Marginal	Microvascular forehead flap and mucosal flap	Metastatic (lungs, lymph nodes)	3b
9. Right shoulder region (brachial nerve)	Marginal	Tikhoff-Linberg	None	3b
10. L1 vertebra region	Marginal	Stabilization of the spine with femur graft and cover with microvascular LD flap	Lungs	3b
11. Left popliteal fossa	Radical	Rotationplasty	None	3b
12. Left acromioclavicular joint and deltoid region	Radical	Pedicular LD flap	Local	3b
13. Right femur medial condyle region	Radical	Tendon reconstruction of medial collateral ligament using semimembranosus tendon	Local	1

ALT: anterolateral thigh; LD: latissimus dorsi.

using the peroneus portion of the sciatic nerve harvested 10–15 cm above the defect. The reason for the limited amount of nerve reconstructions was the fact that the completed resections were already long-lasting and involved major nervous structures, which were not technically possible to reconstruct using grafts. Additionally, the prognosis of the nerve would have been poor due to receiving the high dose of radiation. Nerve reconstruction was performed during the main tumor resection surgery.

One tumor case involved tendon reconstruction of the medial collateral ligament using a semimembranosus tendon.

Survival analysis

A Kaplan–Meier survival curve was plotted to visualize the survival function of the studied tumor cases (Figure 2). The longest follow-up time for a single tumor case was defined to be 88 months. Eight patients were censored, mostly due to their documented follow-up time being shorter than 88 months. The last patient was marked as a censored patient, and so one death was not included in this curve. The presence of many censored data points

distorted the curve and complicated its interpretation. However, the median survival time for the patients was 60 months. The 5-year survival percentage was calculated to be 50.

Discussion

Malignant nerve sheath tumors are a rare group of sarcomas. Due to their rarity, extensive and large-scale research is hard to conduct, and most of the information known to date is based on retrospective analyses of small sample groups. The largest single-institution series contained 205 patients [5]. There is no universal treatment strategy for MPNST, but studies show that the basis of treatment relies on complete surgical resection with confirmed wide margins [4].

Due to the special nature of MPNSTs caused by the origin of deep nerves, their effect on deep nerve tissues, their proximal location, and their often high-grade malignancy, achieving a wide surgical margin is demanding. It can be achieved only by performing mutilating surgery or major amputation. In many cases, surgery alone does not give adequate local control. Hence,

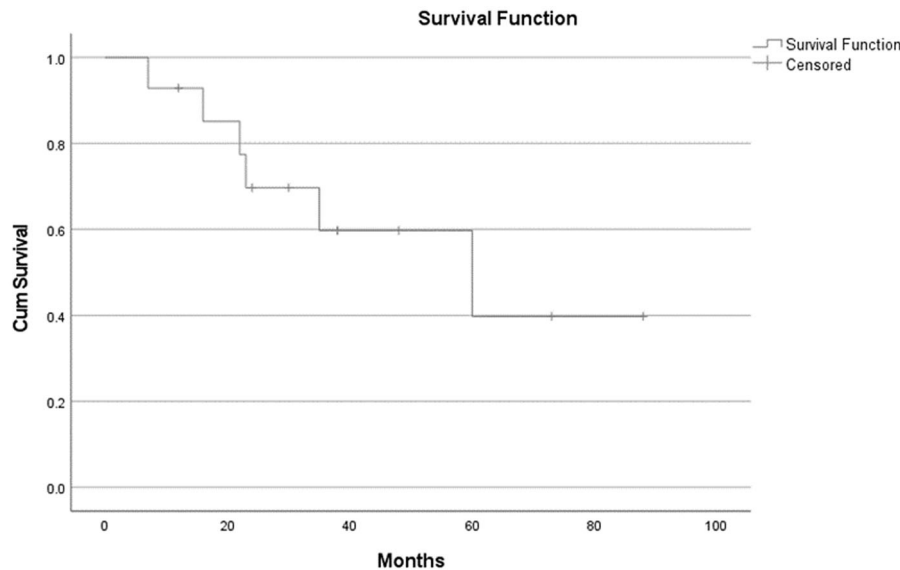


Figure 2. Kaplan–Meier survival curve for 14 malignant peripheral nerve sheath tumor cases after primary surgery treated in Helsinki University Hospital during the years 1991–2021.

adjuvant therapy is often added to a patient’s treatment plan. The use of post-operative radiation therapy has been shown in multiple studies to increase local control of high-grade soft tissue sarcomas in extremities [5,16]. However, numerous studies have not determined radiation therapy to be a prognostic factor affecting local control or overall survival [22,23].

The Scandinavian Sarcoma Group has outlined recommendations concerning radiation therapy for adult extremity and trunk wall soft tissue sarcomas. These guidelines were implemented in the formation of the patient treatment plans evaluated in this study. The protocols and results of chemotherapy as adjuvant treatment are even more varying than those of radiotherapy [15]. The first-line chemotherapy treatment received by three tumors in this study was an ifosfamide-doxorubicin (Adriamycin) regimen, which has been shown to give the best response for treating MPNST [24].

Retrospective analysis conducted in this study showed that 12 (85.7%) tumors received adjuvant treatment. Eight (67%) of these received radiation therapies preoperatively and 3 (25%) post-operatively. Chemotherapy was used in combination with radiation therapy in one tumor case preoperatively and in one case post-operatively. One tumor received post-operative chemotherapy solely. Our study could not demonstrate any relation between chosen adjuvant treatment and the survival of patients.

The results of this retrospective study were mostly congruent with previous studies. Most (64%) tumor cases in this study were identified to be NF1 related and 21% appeared sporadically. Furthermore, 14% were associated with previously received radiation therapy. The mean age of patients with NF1-related tumors during diagnosis was 30.8 years, whereas patients with tumors related to radiation therapy were diagnosed at a significantly later age, 54.5 years. Wanebo et al. registered a similar mean age (29.4 years) for patients with NF1 [25]. The mean age of patients with sporadic tumors in this study was 58.3 years. Two radically excised tumors experiencing recurrence were associated with NF1, supporting the theory that NF1-related tumors are more aggressive and prone to reoccur [4]. MPNSTs are most likely to metastasize to the lungs [26], which was also demonstrated in this study. The occurrence of metastasis was a significant negative prognostic factor in our study, which is similar to the findings published

by Goertz et al. [27]. The mean tumor size at the time of diagnosis was 7.9 ± 2.6 cm, which is slightly larger than the average tumor size described in a study by Stucky et al. evaluating 175 MPNST cases [28]. The reason for this could be that the tumors requiring the most complex reconstructions were sent to our unit.

Our study demonstrated multiple findings which were to some extent divergent from those in the literature. Eighty-three percent of the patients with tumors located on the trunk were alive during follow-up, while only 33% with tumors located on the extremities were alive. None of the patients with tumors originating in the head region were alive during follow-up. The average size of tumors located on the extremities was 7.2 cm, while the average size of tumors located on the trunk was 7.8 cm. Hence, we did not find a statistically significant difference between the size of the tumor and its location. However, a small patient sample in our study makes it not possible to draw statistically significant conclusions. Previous studies have demonstrated opposite findings, with tumors located on the extremities having a better prognosis than tumors located on the trunk and with Kahn et al. demonstrating that those with lesions in the truncal region fared worse than those with lesions in the extremities ($p = 0.01$) [16]. This is thought to be due to peripheral tumors being more susceptible to wide-margin surgery as well as earlier detection.

The most significant prognostic factors found in previous publications are tumor size and NF1 relation [4,29]. The largest retrospective analysis examining prognostic factors for survival of patients with resectable MPNST was carried out by Lazarev et al. in 2017 and included 1,022 patients. Their calculated 5-year overall survival was 58% [30]. More specifically, Kahn and colleagues demonstrated an NF1-related overall survival (median) of 22.1 months and for sporadic tumors 64.3 months in one single-institute study [16]. The results of our study demonstrate a similar trend with sporadic tumors having a better prognosis than NF1-related tumors. Tumors related to NF1 are considered more aggressive than sporadic tumors, which explains their poor survival rate.

This study demonstrates that wide margin surgery alone does not assure favorable results for this aggressive tumor: 66% of radically excised tumors recurred within 18 ± 8.5 months of primary operation. However, patients with tumors excised radically were

all alive during follow-up, suggesting that radical excision may have a positive prognostic effect on survival.

Due to the rarity of this tumor, only a small sample of patients with MPNST presented to a single clinical center, which limits the sample size of the research and the collection of statistically significant data. Also, complex reconstruction procedures can be overrepresented, as these procedures are centralized at Helsinki University Hospital. Additionally, retrospective analysis poses its own limitations and weaknesses. Although the research included only a small data sample, a detailed analysis of patient treatment for this rare sarcoma with poor prognosis may help to identify optimal care, and so we consider it useful to publish this research.

The rarity of this sarcoma requires multicenter studies to gather a significant amount of data. Only this can assure the finding of a scientifically proven optimal treatment plan for MPNST. To our knowledge, there are no studies focusing on the evaluation of the patient quality of life after a specific treatment plan, as the focus is usually on the effect of treatments and prognosis.

The known strong relation between MPNST and NF1 could in the future be an indication for screening patients with NF1 for malignancy. The screening method should be safe, fast, and cheap. Schwabe and colleagues have suggested algorithms based on magnetic resonance imaging and positron-emission tomography image findings for the evaluation and management of MPNST [31]. Park and colleagues have identified two serum markers, insulin-like growth factor binding protein 1 and regulated upon activation, normal T-cell expressed and secreted (RANTES), which were significantly increased in patients with NF1 and MPNST compared with patients with NF1 and no presence of MPNST [32].

Conclusion

MPNST is a rare tumor that is often detected late due to its impact on nerves, which are typically deep within tissues. By their nature, MPNSTs require resection with at least clear surgical margins, which often indicates major resection and reconstruction. Nevertheless, with these measures, a disease-free state is achievable during a 3-year follow-up. The relatively poor prognosis of MPNST despite adjuvant treatment and surgery means that patient well-being and quality of life should be prioritized and examined more closely. Additionally, screening for MPNST in patients with NF1 should be implemented to detect these tumors earlier and improve the prognosis.

Synopsis

The main factors affecting the survival prognosis for MPNST are the status of the resection margins and neurofibromatosis type 1 relation. The achievement of wide margin excision often indicates complex resection and reconstruction.

Disclosure statement

No potential conflict of interest was reported by the author(s).

Funding

This research received no specific grant from any funding agency in the public, commercial, or not-for-profit sectors.

Data availability statement

The data that support the findings of this study are available on request from the corresponding author. The data are not publicly available due to privacy and ethical restrictions.

References

- [1] Sharma S, Shah J, Bali H. Malignant peripheral nerve sheath tumor: a rare malignancy. *J Oral Maxillofac Pathol.* 2020; 24(4):86.
- [2] Farid M, Demicco E, Garcia R, et al. Malignant peripheral nerve sheath tumors. *Oncologist.* 2014;19(2):193–201.
- [3] Ogawa B, Skaggs D, Kay R. Malignant peripheral nerve sheath tumor of the lumbar spine. *Am J Orthoped.* 2009; 38:89–92.
- [4] Ducatman B, Scheithauer B, Piepgras D, et al. Malignant peripheral nerve sheath tumors. A clinicopathologic study of 120 cases. *Cancer.* 1986;57(10):2006–2021.
- [5] Anghileri M, Miceli R, Fiore M, et al. Malignant peripheral nerve sheath tumors. *Cancer.* 2006;107(5):1065–1074.
- [6] Watson K, Al Sanna G, Kivlin C, et al. Patterns of recurrence and survival in sporadic, neurofibromatosis type 1-associated, and radiation-associated malignant peripheral nerve sheath tumors. *J Neurosurg.* 2017;126(1):319–329.
- [7] National Cancer Institute. Malignant peripheral nerve sheath tumor. National Cancer Institute [Internet]. 2020 [cited 2022 Jan 26]. Available from: <https://www.cancer.gov/pediatric-adult-rare-tumor/rare-tumors/rare-soft-tissue-tumors/mpnst>
- [8] Gladdy R, Qin L, Moraco N, et al. Do Radiation-Associated soft tissue sarcomas have the same prognosis as sporadic soft tissue sarcomas? *J Clin Oncol.* 2010;28(12):2064–2069.
- [9] Korf B. Malignancy in neurofibromatosis type 1. *Oncologist.* 2000;5(6):477–485.
- [10] Geller D, Gebhardt M. MPNST: diagnosis, treatment, prognosis and research [Internet]. Liddy Shriver Sarcoma Initiat; 2016 [cited 2021 Dec 7]. Available from: <http://sarcoma-help.org/mpnst.html>
- [11] Collin C, Godbold J, Hajdu S, et al. Localized extremity soft tissue sarcoma: an analysis of factors affecting survival. *J Clin Oncol.* 1987;5(4):601–612.
- [12] Smolle M, Andreou D, Tunn P, et al. Diagnosis and treatment of soft-tissue sarcomas of the extremities and trunk. *EFORT Open Rev.* 2017;2(10):421–431.
- [13] Arifi S, Belbaraka R, Rahhali R, et al. Treatment of adult soft tissue sarcomas: an overview. *Rare Cancers Ther.* 2015;3: 69–87.
- [14] Scandinavian Sarcoma Group [Internet]. 2021 [cited 2021 Dec 15]. Available from: <https://www.ssg-org.net/>
- [15] Zehou O, Fabre E, Zelek L, et al. Chemotherapy for the treatment of malignant peripheral nerve sheath tumors in neurofibromatosis 1: a 10-year institutional review. *Orphanet J Rare Dis.* 2013;8:127.
- [16] Kahn J, Gillespie A, Tsokos M, et al. Radiation therapy in management of sporadic and neurofibromatosis type 1-Associated malignant peripheral nerve sheath tumors. *Front Oncol.* 2014;4(324). doi:10.3389/fonc.2014.00324
- [17] Trovik C, Bauer H, Styning E, et al. The Scandinavian Sarcoma Group Central Register: 6,000 patients after 25 years of monitoring of referral and treatment of extremity and trunk wall soft-tissue sarcoma. *Acta Orthop.* 2017;88(3): 341–347.

- [18] Enneking W, Spanier S, Goodman M. A system for the surgical staging of musculoskeletal sarcoma. *Clin Orthop*. 1980;153:106–120.
- [19] Hermanek P, Wittekind C. Residual tumor (R) classification and prognosis. *Semin Surg Oncol*. 1994;10(1):12–20.
- [20] Tukiainen E, Kantonen I, Koivisto-Korander R. Pehmytkudossarkoomien kirurginen hoito [Surgical treatment of soft tissue sarcomas]. *Duodecim Laaketieteellinen Aikakauskirja*. 2015;71:1247–1253.
- [21] Sandy G, Shores J, Reeves M. Tikhoff-Linberg procedure and chest wall resection for recurrent sarcoma of the shoulder girdle involving the chest wall. *J Surg Oncol*. 2005;89(2):91–94.
- [22] Yang J, Chang A, Baker A, et al. Randomized prospective study of the benefit of adjuvant radiation therapy in the treatment of soft tissue sarcomas of the extremity. *J Clin Oncol*. 1998;16(1):197–203.
- [23] Carli M, Ferrari A, Mattke A, et al. Pediatric malignant peripheral nerve sheath tumor: the Italian and German soft tissue sarcoma cooperative group. *J Clin Oncol*. 2005;23(33):8422–8430.
- [24] Kroep J, Ouali M, Gelderblom H, et al. First-line chemotherapy for malignant peripheral nerve sheath tumor (MPNST) versus other histological soft tissue sarcoma subtypes and as a prognostic factor for MPNST: an EORTC soft tissue and bone sarcoma group study. *Ann Oncol*. 2011;22(1):207–214.
- [25] Wanebo J, Malik J, Vandenberg S, et al. Malignant peripheral nerve sheath tumors. A clinicopathologic study of 28 cases. *Cancer*. 1993;71(4):1247–1253.
- [26] Stark A, Buhl R, Hugo H, et al. Malignant peripheral nerve sheath tumours – report of 8 cases and review of the literature. *Acta Neurochir*. 2001;143(4):357–364.
- [27] Goertz O, Langer S, Uthoff D, et al. Diagnosis, treatment and survival of 65 patients with malignant peripheral nerve sheath tumors. *Anticancer Res*. 2014;34(2):777–783.
- [28] Stucky C, Johnson k, Gray R, et al. Malignant peripheral nerve sheath tumors (MPNST): the Mayo Clinic experience. *Ann Surg Oncol*. 2012;19(3):878–885.
- [29] Porter D, Prasad V, Foster L, et al. Survival in malignant peripheral nerve sheath tumours: a comparison between sporadic and neurofibromatosis type 1-associated tumours. *Sarcoma*. 2009;2009:756395.
- [30] Lazarev S, Demicco E, Gupta V. Prognostic factors for survival in resectable malignant peripheral nerve sheath tumors. *Int J Radiat Oncol*. 2017;99(2):E755.
- [31] Schwabe M, Spiridonov S, Yanik E, et al. How effective are noninvasive tests for diagnosing malignant peripheral nerve sheath tumors in patients with neurofibromatosis type 1? Diagnosing MPNST in NF1 patients. *Sarcoma*. 2019;2019:4627521–4627528.
- [32] Park S, Sawitzki B, Kluwe L, et al. Serum biomarkers for neurofibromatosis type 1 and early detection of malignant peripheral nerve-sheath tumors. *BMC Med*. 2013;11:109.